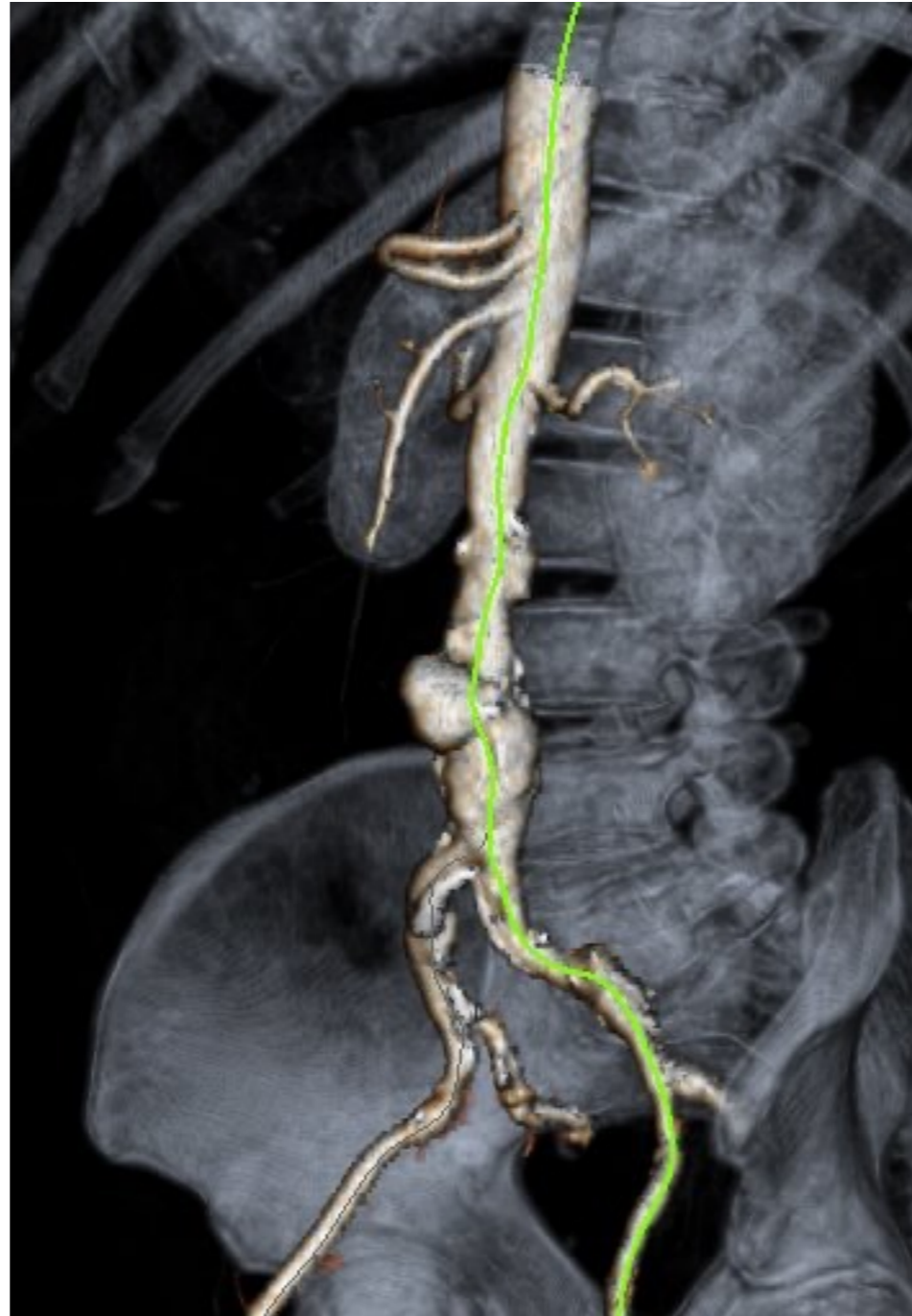



CASE #1


EVAR + IMA embolization

Friday, December 10th, 2021




Medical History

- Male 61 yo
- Alcoholism
- Tobacco use
- Hypertension
- Psoriasis
- Claudicant



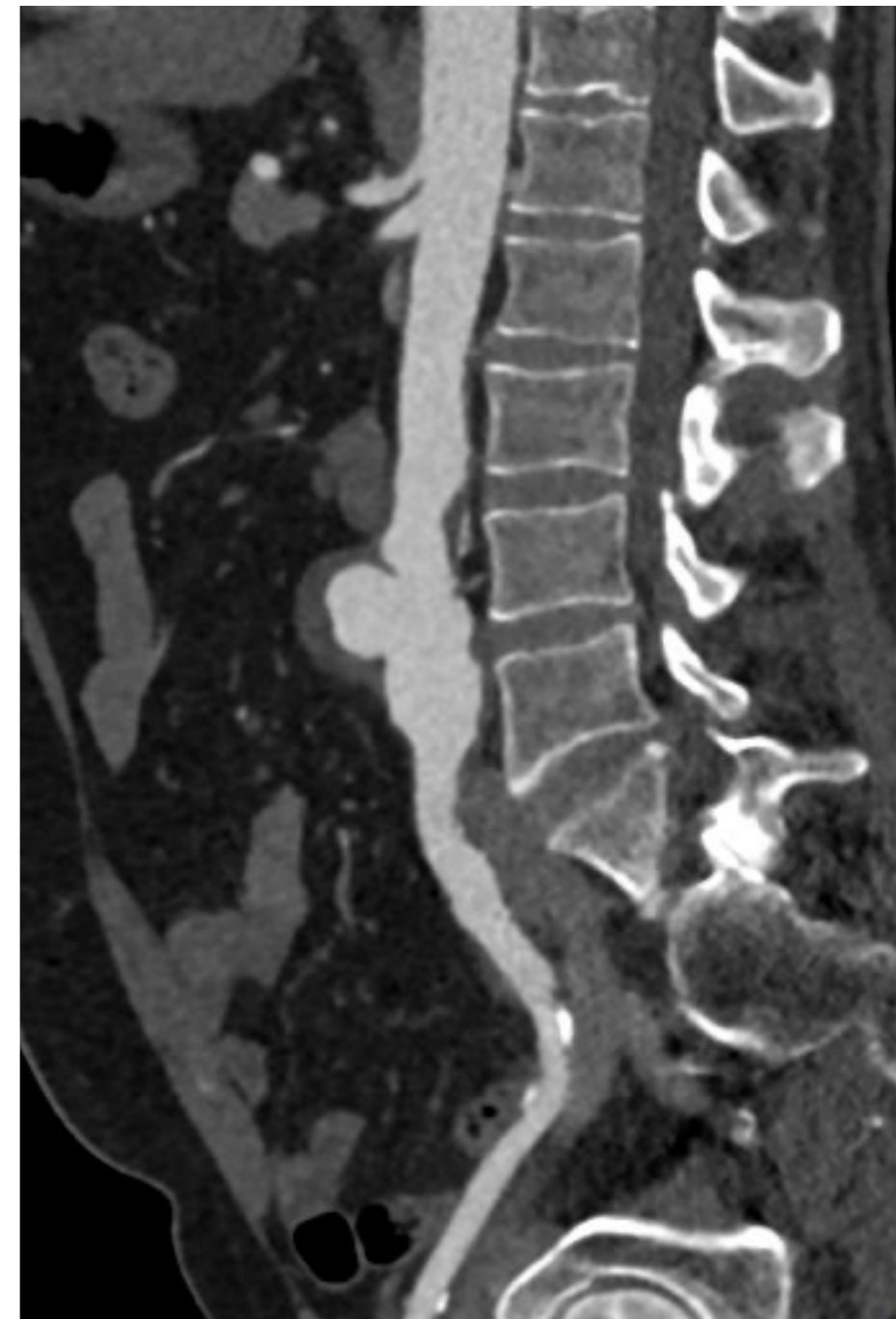
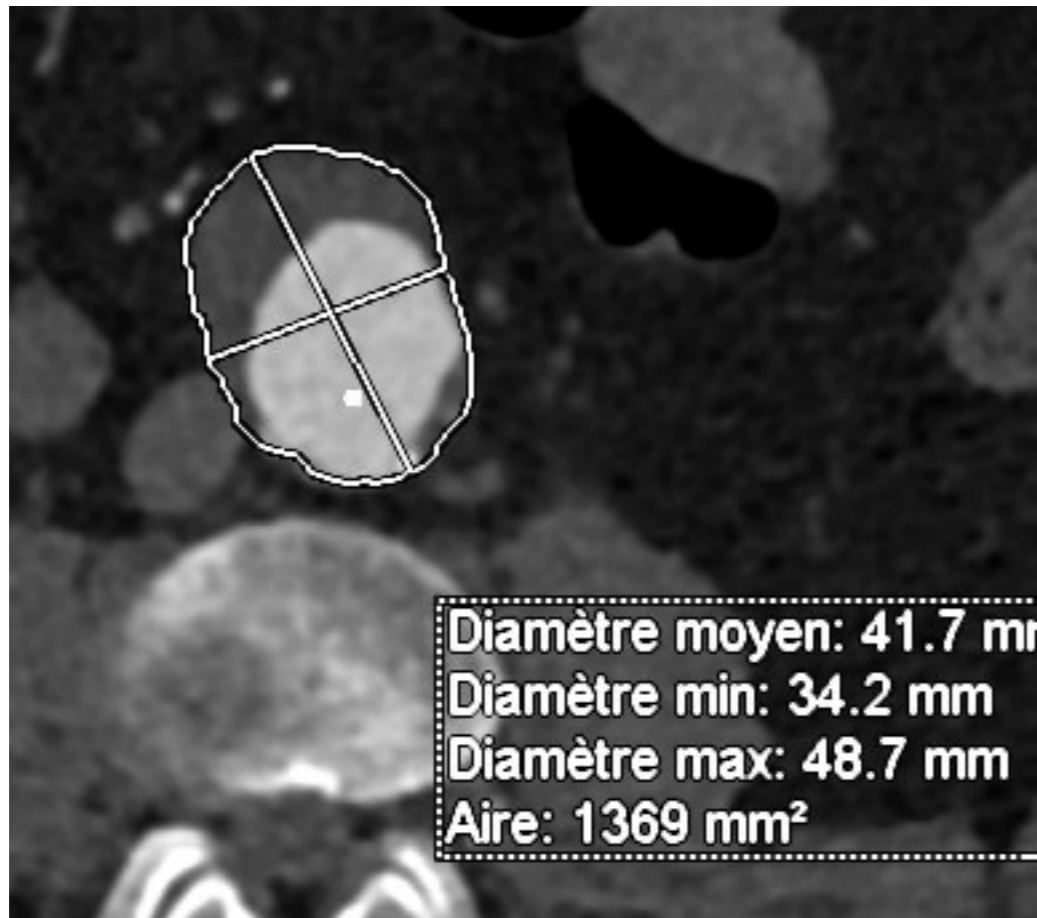
Pre operative work-up

- **Respiratory function test:** normal
- **Trans-thoracic echocardiography:** normal kinetics, LVEF 65%
- ASA 3



Anatomical evaluation

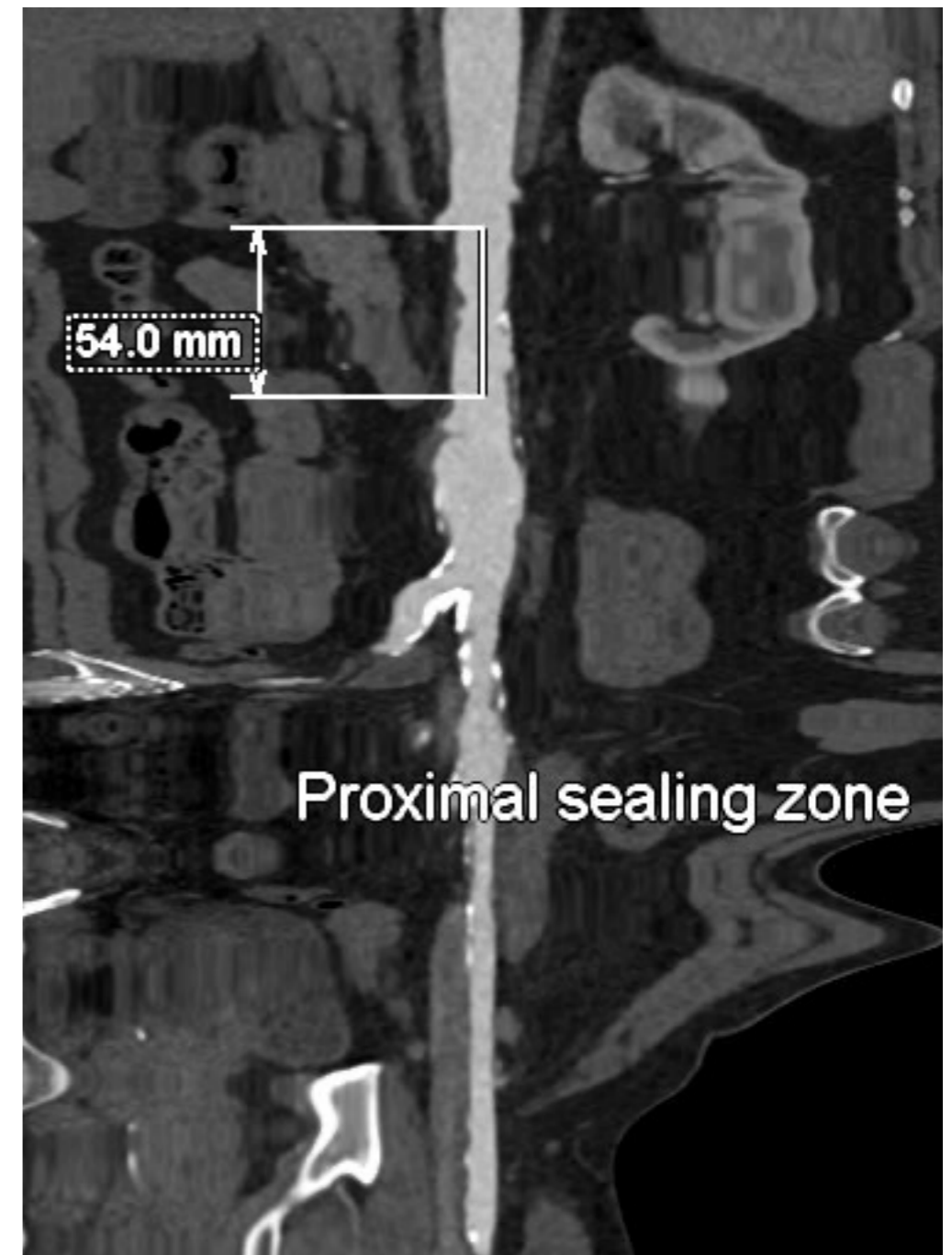
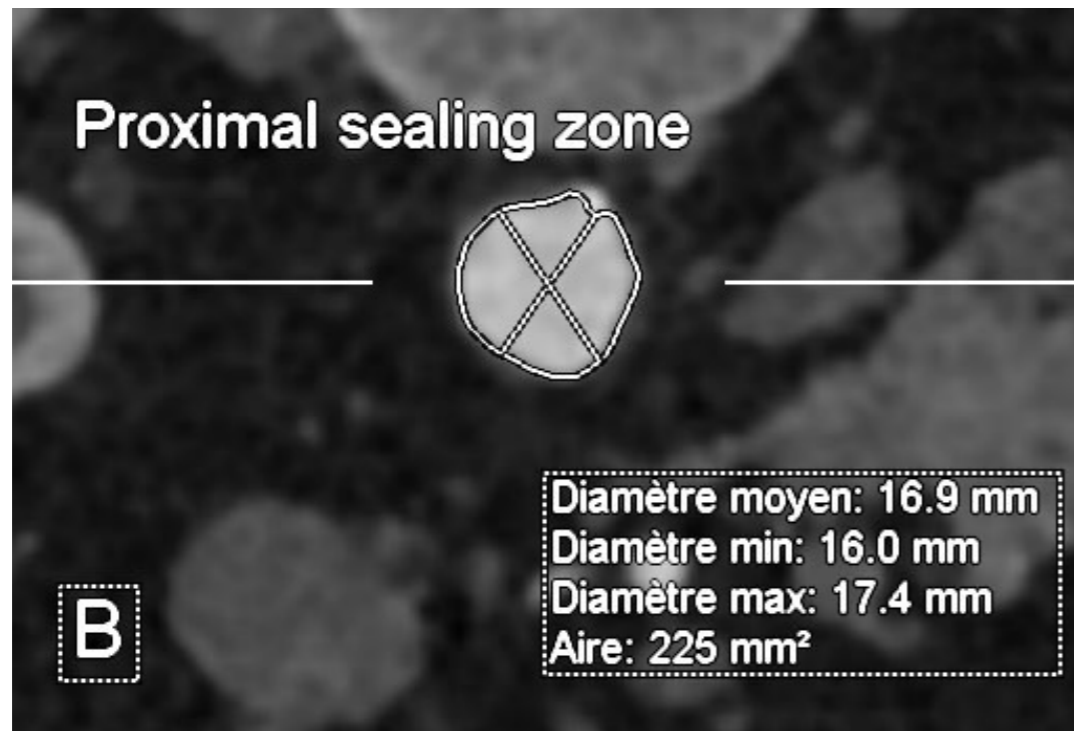
Penetrating Ulcer



Anatomical evaluation

Proximal sealing zone

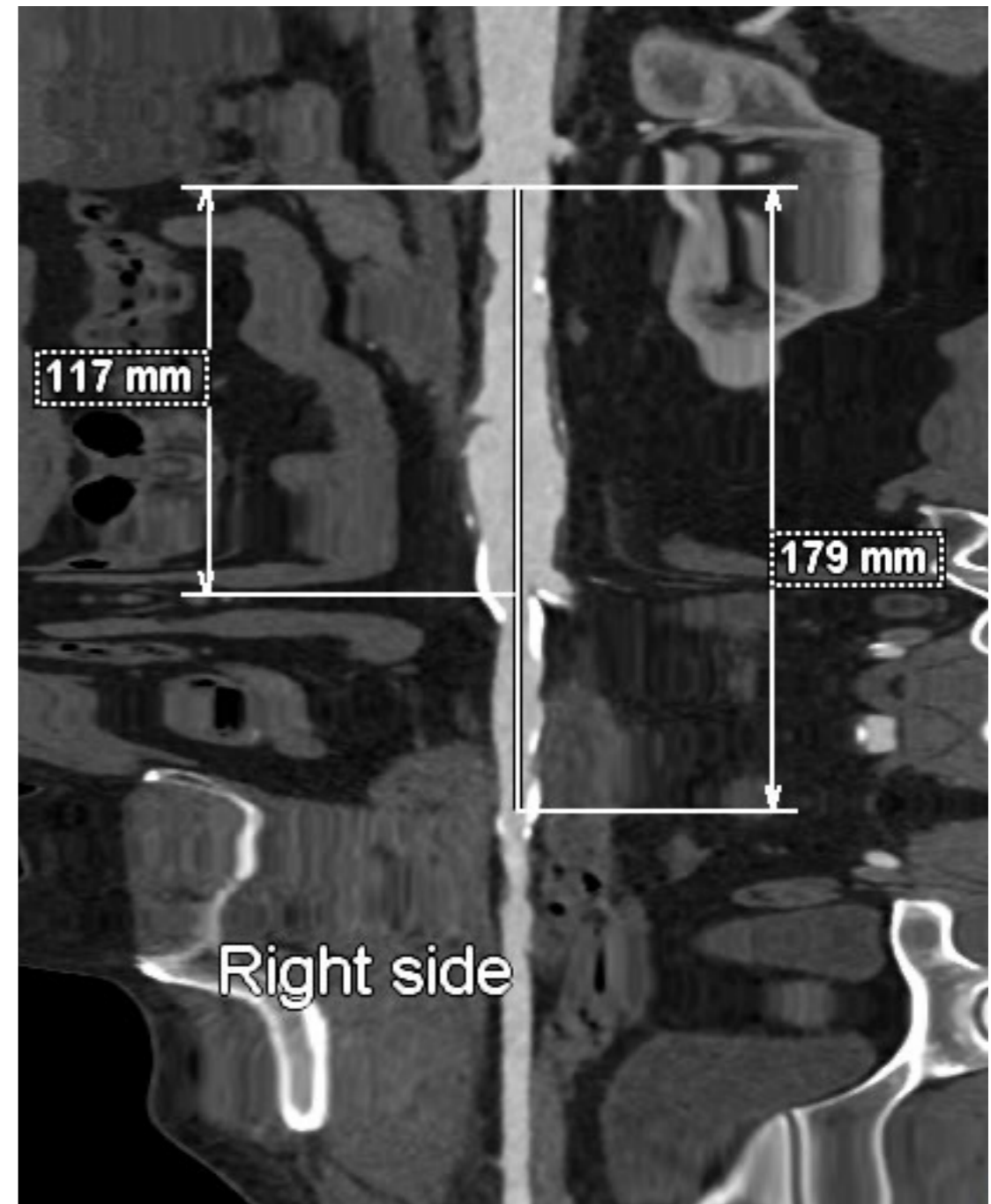
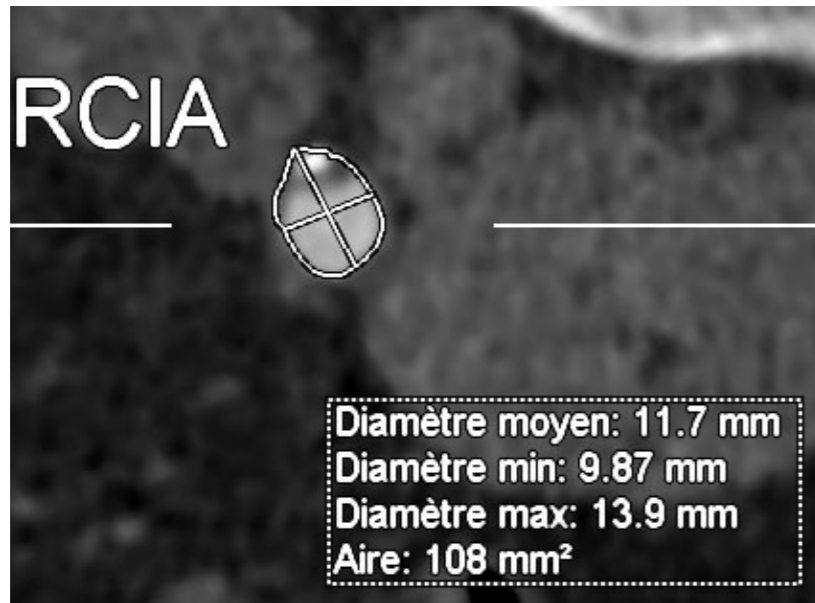- Diameter: 17 mm
- Length: 54 mm



Anatomical evaluation

Right iliac access

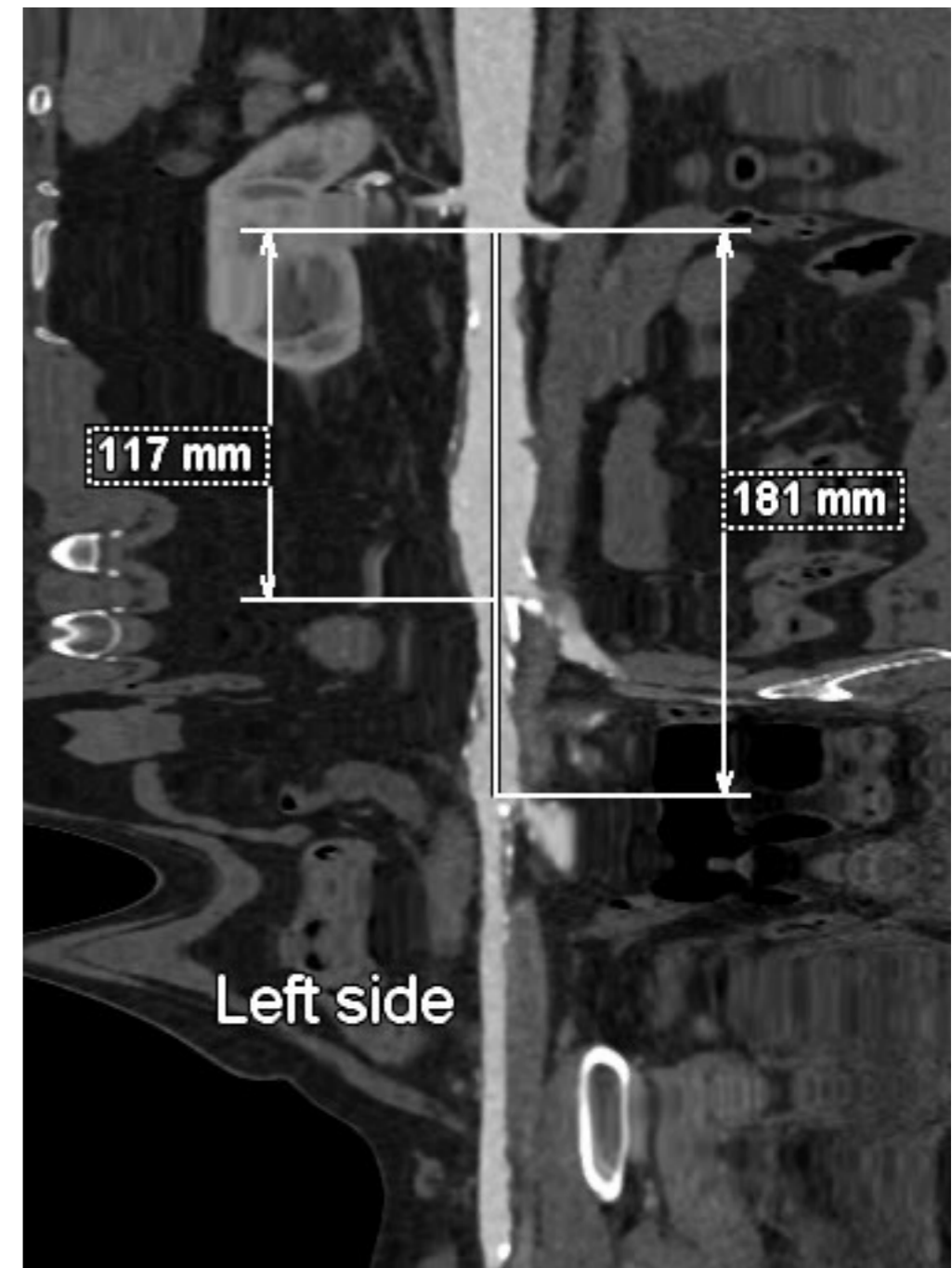
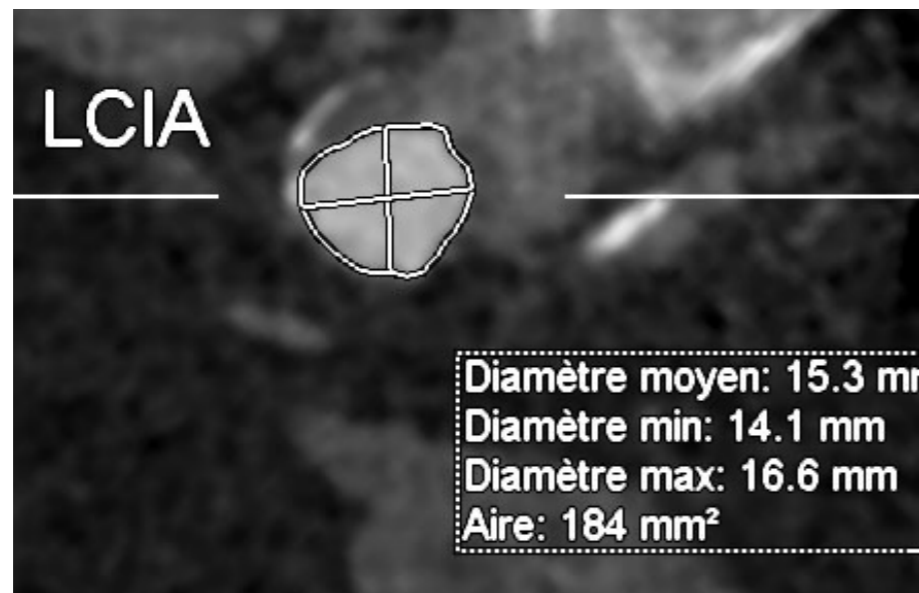- Sealing zone RCIA
- Diameter max: 14 mm



Anatomical evaluation

Left iliac access

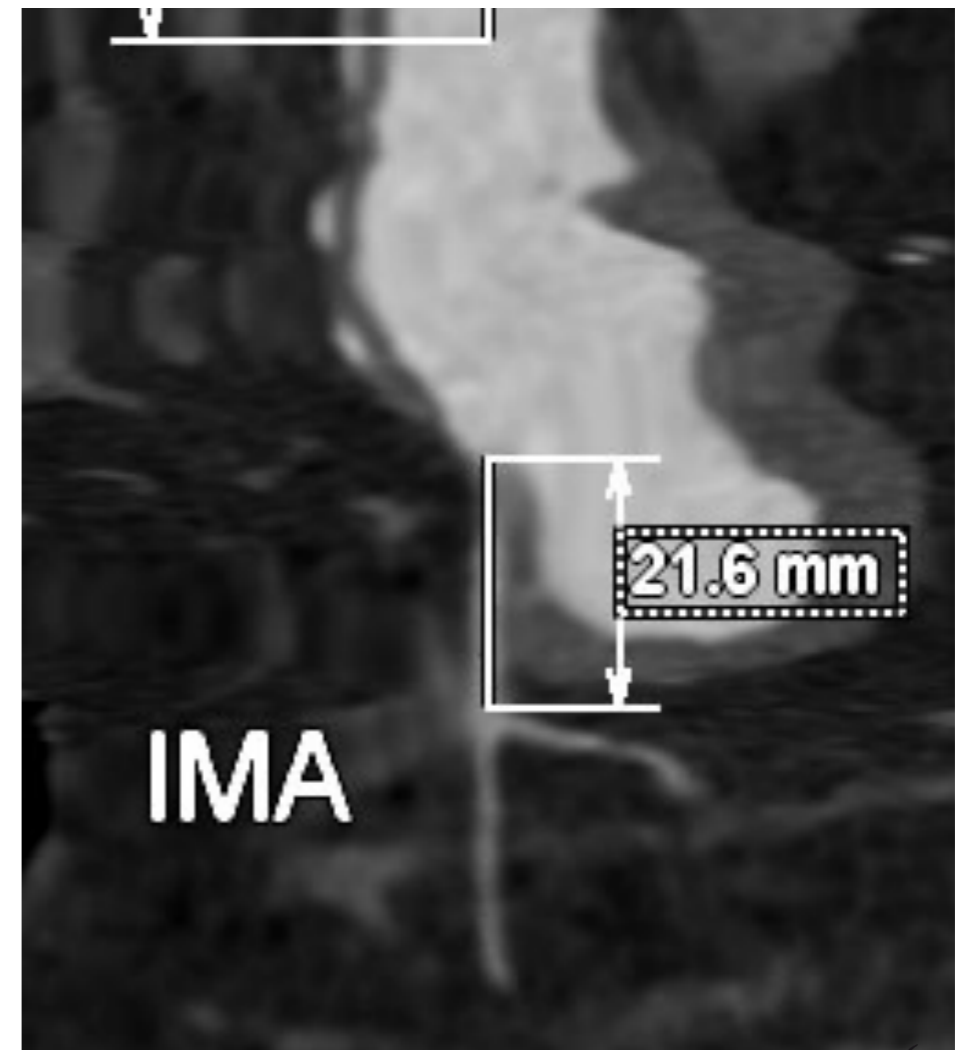
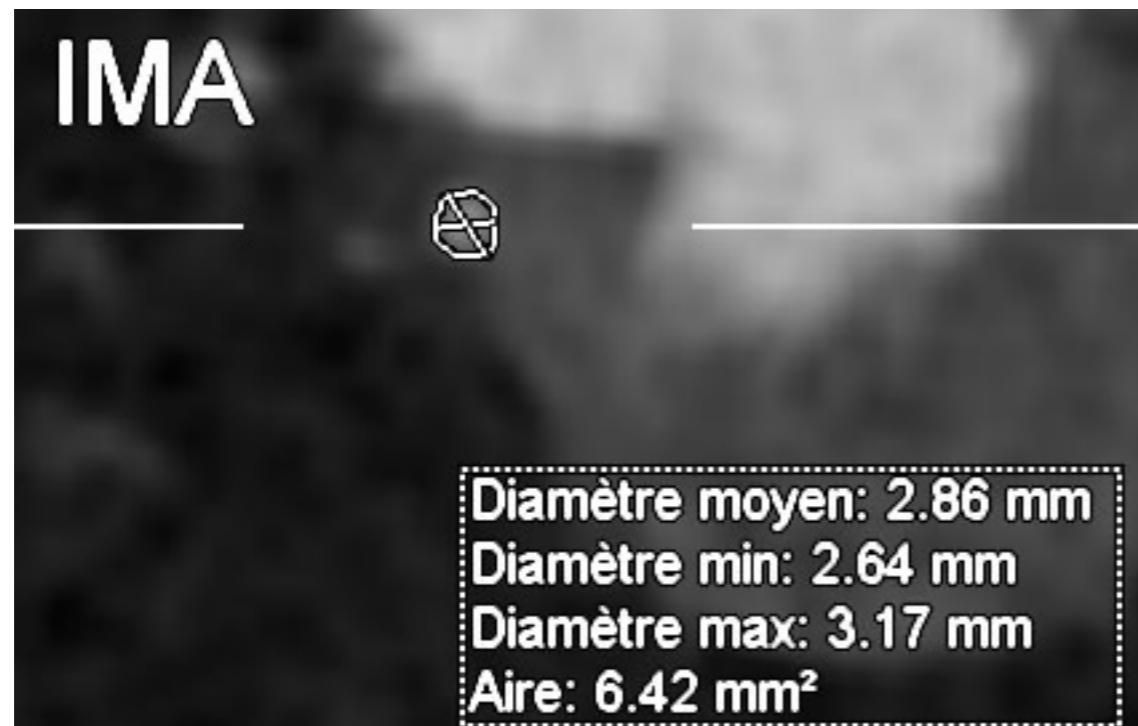- Sealing zone LCIA
- Diameter max: 16,6 mm



Anatomical evaluation


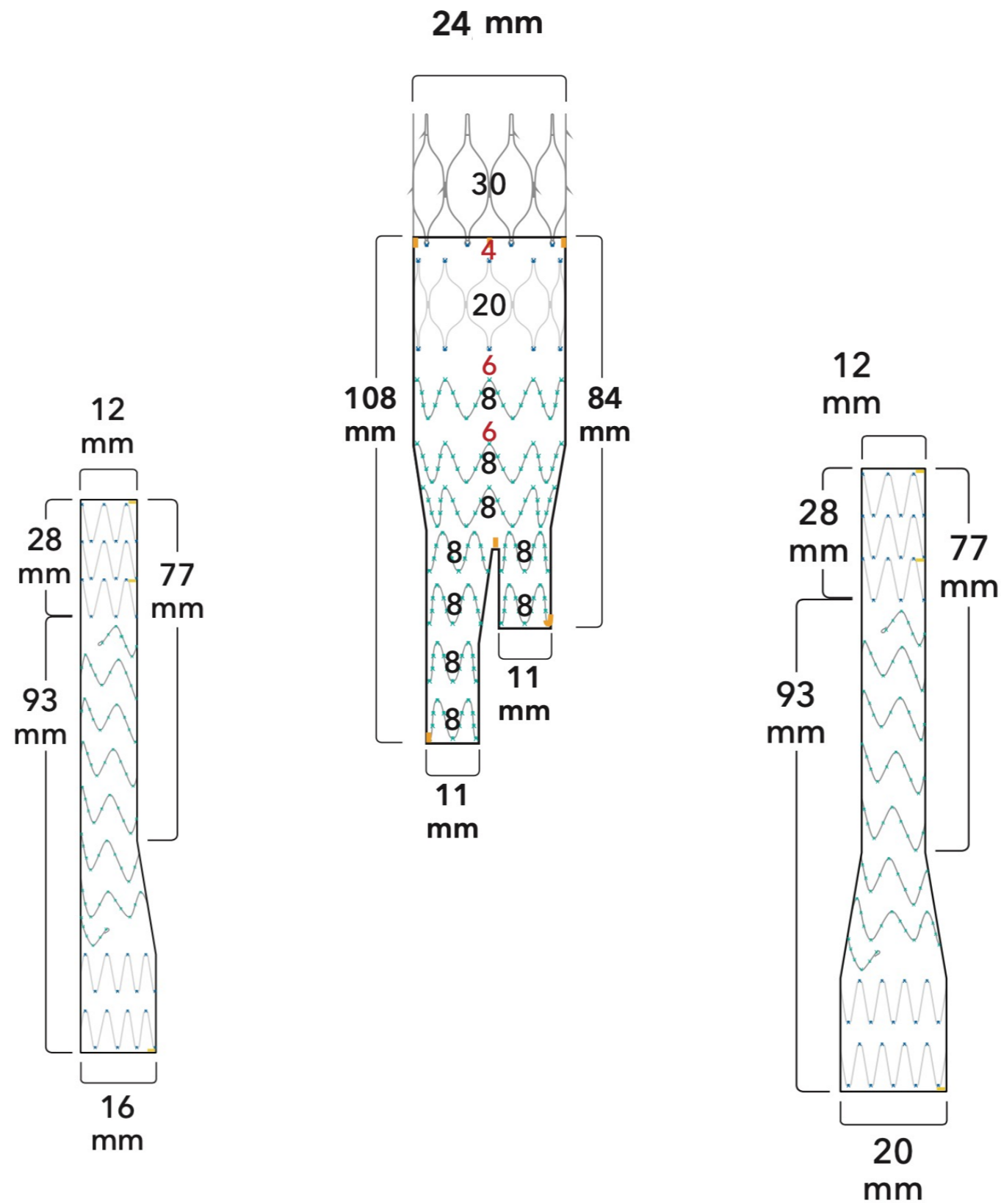
Inferior mesenteric artery embolization

- Diameter: 3 mm
- First bifurcation: 22 mm



Graft plan

EVAR



Required Accessories

Guide wires

- J-tip Teflon wire (x2)
- 0,035'' curved Lunderquist® 260 cm extra-stiff wire (x2)
- 0,0035'' J-tip Redifocus® Terumo© 260 cm

Sheath

- 7Fr short (10cm) sheath (x2)
- 10Fr short (10cm) sheath (x2)
- Aptus 7Fr 55cm steerable sheath

Catheter

- 5Fr Pigtail catheter (100cm)
- KMP Beacon® catheter COOK© (100cm)

Other

- Perclose ProStyle Abbott© (x4)
- Compliant balloon catheter CODA
- 12-40 mm long shaft semi compliant balloon Mustang® (X2)
- 5 mm AVP4 or coils

Procedure

US guided percutaneous bilateral femoral puncture

1. **R & L**: 7 Fr. sheath

50 U/kg heparin

2. Registration of fusion mask

3. Preclosing : 2 proglides on each side

4. **R & L**: 10 Fr. sheath

5. **R** : Advance Aptus over Rosen/ IMA embolization with KMP and AVP4 or coils

6. **L** : Pigtail angiocatheter to just above renals

7. **R** : Lunderquist in ascending aorta / Advance bifurcated endograft

8. **L** : Aortic angiogram / adjustment of the fusion mask

9. **R** : Deployment of bifurcated part

10. **L** : Retrieve Pigtail catheter

11. **L** : Contro-lateral limb catheterization with KMP and Terumo / Angio from the groin

12. **L** : Advance left limb on Lunderquist / Contro lateral limb deployment

13. **R** : Ipsilateral limb deployment

14. **R** : Angio from the groin

15. **R** : Advance ipsilateral limb

16. **R** Coda inflation

17. **R & L**: Kissing angioplasty